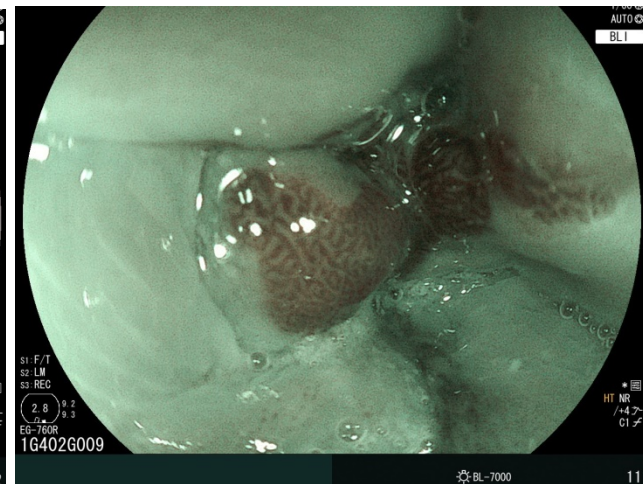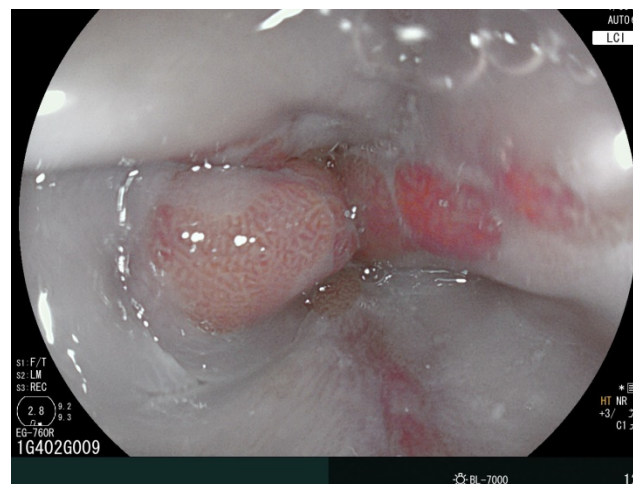

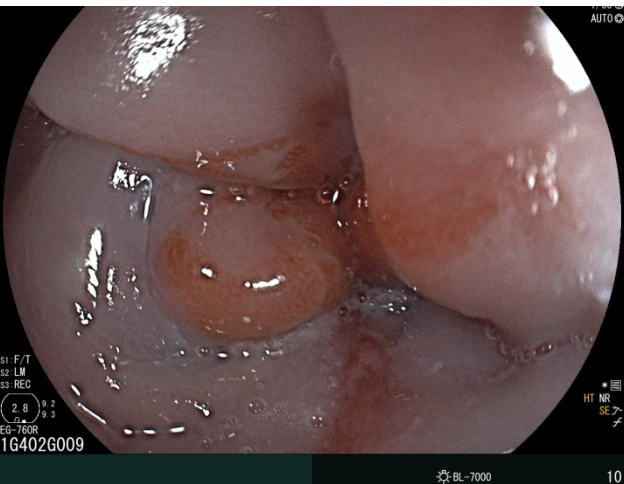
## Comparison of White Light to Fujifilm Linked Color Imaging (LCI<sup>®</sup>) and Blue Light Imaging (BLI)



*White Light*

*LCI*

*BLI*

*Mucosal changes in the esophageal lining, indicating Barrett's epithelium.*