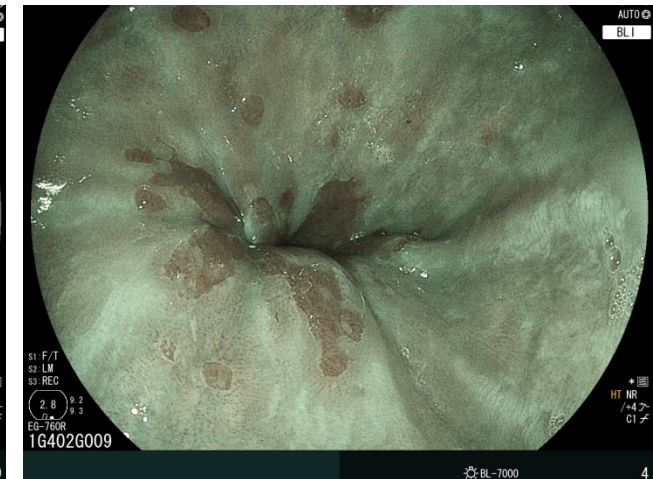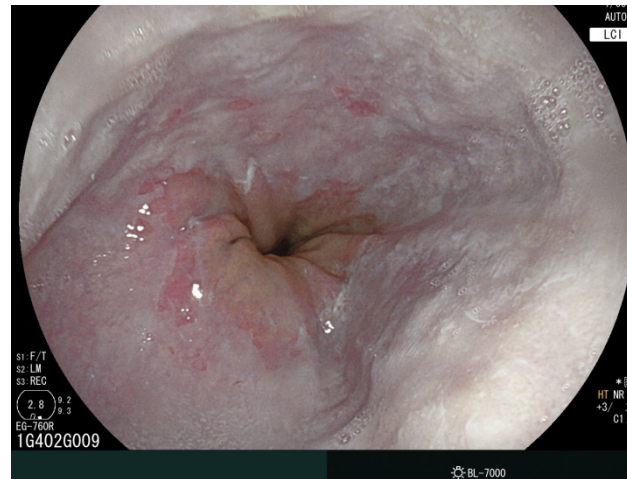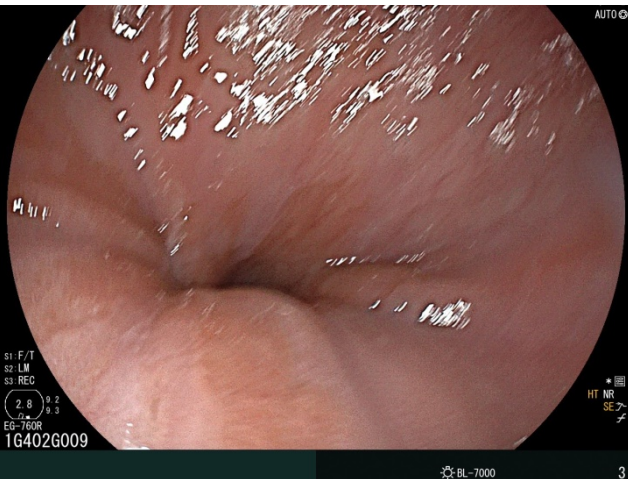


Comparison of White Light to Fujifilm Linked Color Imaging (LCI[®]) and Blue Light Imaging (BLI)



White Light

LCI

BLI

Mucosal changes in the GE junction, indicating Barrett's epithelium.